



Critical Study On Types Of Sports Injuries

Harisadhan Betal Research Scholar, Department of Physical Education, Sri Satya Sai University of Technology & Medical Sciences, Sehore, M.P.

Dr. Minakshi Pathak Research Guide, Department of Physical Education, Sri Satya Sai University of Technology & Medical Sciences, Sehore, M.P.

Received:09.03.2020 , Revised:11.04.2020 , Accepted:13.05.2020

ABSTRACT:

Sports-related injuries are frequent and can affect bones, muscles, tendons, ligaments, and other body parts. Many minor injuries can be treated at home using rest, ice, compression, elevation, and over-the-counter painkillers. However, some injuries need medical attention, including surgery, physical therapy, and immobilization. This paper reflects critical study on types of Sports Injuries.

Keywords : sports , injuries , classification , tissue.

SPORTS INJURIES- CLASSIFICATION

Various writers mention a variety of classification categories for sports injuries. Athletic injuries can be classed based on the sport or the location of the injury on the body. Some doctors and athletic trainers divide athletic injuries into categories based on the type of participant, such as women, youth, children, or elderly players. The labels "acute" and "chronic" are used in yet another classification scheme. Another way to categorise athletic injuries is by the type of tissue damaged, which includes soft tissue and hard tissue (Morris, 1984).

Morris (1984), have classified sports injuries as -

- i. **By sports** - Football, Track and Field, Volleyball etc.
- ii. **By participant group** - Women, Men, Youth, Children etc.
- iii. **By nature of injury** - Chronic and acute.
- iv. **By type of tissue involved** - Soft tissue and hard tissue.
- v. **By anatomical location** - Shoulder, Knee, Wrist, Ankle etc.

vi. **According to nature of game** - Team game, individual game etc.

SPORTS INJURIES- TYPES

Sports activities can result in injuries - some minor, some serious, and still others resulting in lifelong medical problems. There are two general types:

a] Acute Traumatic Injury

And

b] Overuse or Chronic Injury

a) Acute Traumatic Injury: Acute traumatic injuries are usually the result of a single blow from a single force application. Acute traumatic injury includes the following injuries: > Strain: A strain is a damage to a muscle or a tendon, the connective tissue between muscles and bones. A strain can be a simple overstretch of the muscle or tendon, or it can result in a partial or total tear, depending on the degree of the injury. Calf muscle strain is an example of strain.

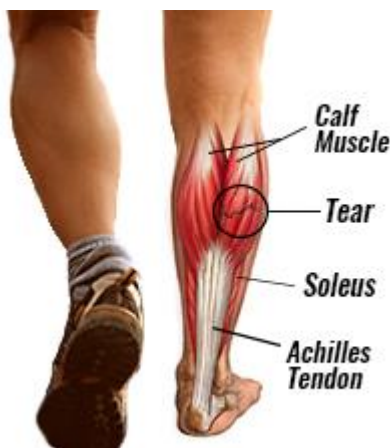

Fig. No. 1.1: Calf muscle strain

Sprain: A sprain is an injury to the ligament, which is the tough, fibrous tissue that joins bones. Ligament injuries occur when this tissue is stretched or torn. Ankle sprain is one example of strain (Quinn, 2011).

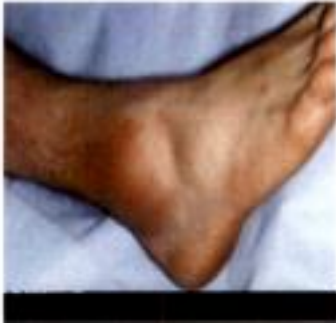

Fig. No. 1.2 Ankle Sprain

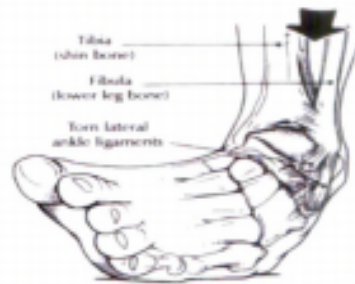


Fig No. 1.3 : Ankle Sprain

A bruise, also known as a muscle contusion, can occur as a result of a fall or contact with a hard surface, equipment, or another player when participating in sports. When muscle fibres and connective tissue are crushed, a bruise develops; torn blood vessels may cause a bluish colour. The majority of bruises are mild, but some can result in more serious injury and consequences **(Carol, 2006)**.

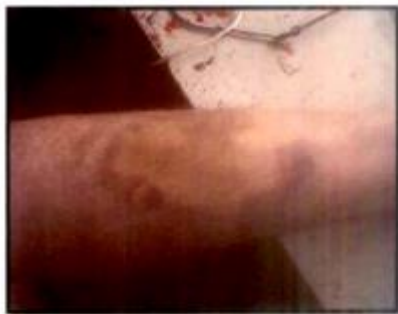

Fig. No. 1.4 : Bruise

Fractures: Also known as shattered bones, fractures are a very common sports injury caused by a one-time bone damage (an acute fracture). With an acute fracture, small fissures might lead to a complete break. Most of these are considered emergencies, and they may require surgery to be fully repaired. These are the injuries to the soft tissues. Bones and teeth are harmed by hard tissue trauma. Fractures, dislocations, and tooth injuries are examples of hard tissue injuries.

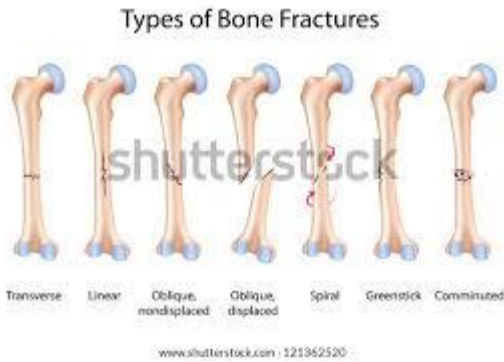

Fig. No. 1.5 :Fractures



Fig. No. 1.6 : Shoulder dislocation

Dislocations are joint injuries in which one bone is displaced from its neighbour. Dislocations occur when a joint moves beyond its normal range of motion (ROM) and causes significant injury to the surrounding tissue.

Laceration: A laceration is a type of open wound that is usually caused by a sharp item. Damage to the skin and underlying tissue is likely. Controlling the bleeding, cleaning the wound with a sterile solution, and covering it with a nonstick dressing are the steps taken to treat this. An incision in the skin that is generally quite deep TM.

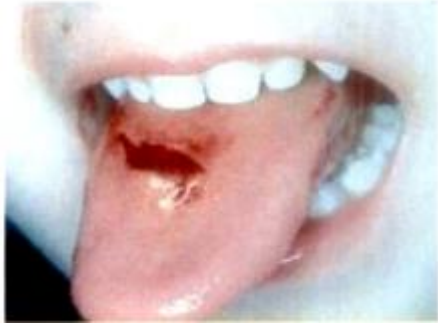

Fig. No. 1.7 : Laceration

The Achilles tendon is the most often damaged tendon in the body. When doing acts that require explosive acceleration, such as pushing off or jumping, rupture might occur. According to several research, the male to female ratio for Achilles tendon rupture ranges from 7:1 to 4:1.

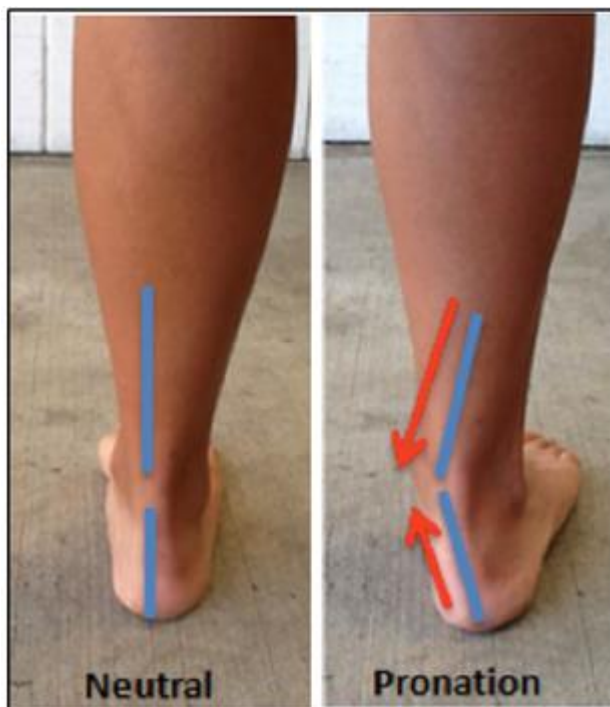

Fig. No. 1.8 : Achilles tendon

The Achilles tendon is most usually injured by forced dorsiflexion of the ankle outside of its normal range of motion, or by rapid plantar flexion or dorsiflexion of the ankle.

b] **Overuse or Chronic Injury:** An overuse or chronic injury is the second form of sports injury. Chronic injuries are those that last for a long time. Repetitive training, such as jogging, overhand throwing, or serving a tennis ball, is the most common cause of chronic

injuries.

These are some of them:

Shin Splints: Pain along the shin bone (tibia) is known as a shin splint. The discomfort normally occurs on the outside of the lower leg, but it can also occur in the foot and ankle (anterior shin splints) or where the bone meets the calf muscles at the inner edge of the bone (internal shin splints) (medial shin splints). Shin splints are frequent among runners, especially those who run on rough surfaces. Shin splints can be caused by a lack of warm-up or stretching, poor running technique, running in shoes with insufficient support, or having "flat feet."

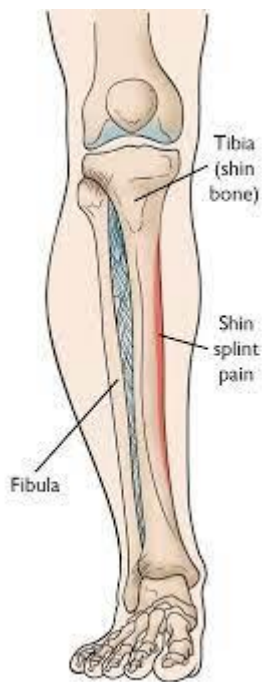


Fig. No. 1.9 : Shin Splint

Tennis elbow is a common overuse ailment in tennis players. It's caused by the forearm muscles, which you use to straighten and lift your hand and wrist, contracting repeatedly.

The tendons that connect the forearm muscles to the bone on the outside of your elbow may get inflamed or tear as a result of the frequent motions and stress. Tennis elbow can be caused by a variety of factors, including repeated usage of the backhand stroke with poor technique, as the name suggests. However, many other typical arm actions, such as screwdriver use, hammering, painting, raking, weaving, and others, can produce tennis elbow injury (Dube, 2008).

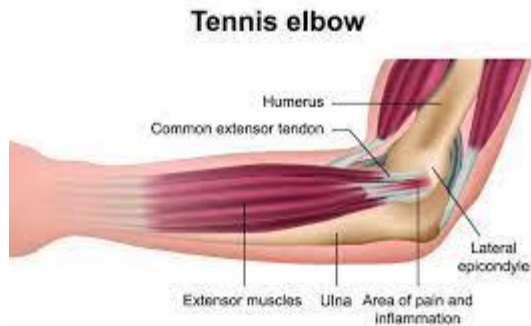


Fig. No. 1.10 : Tennis Elbow

An overuse injury is referred to as a stress fracture. It happens when muscles get exhausted and unable to tolerate additional trauma.

The exhausted muscles eventually transfer the tension overload to the bone, resulting in a stress fracture.

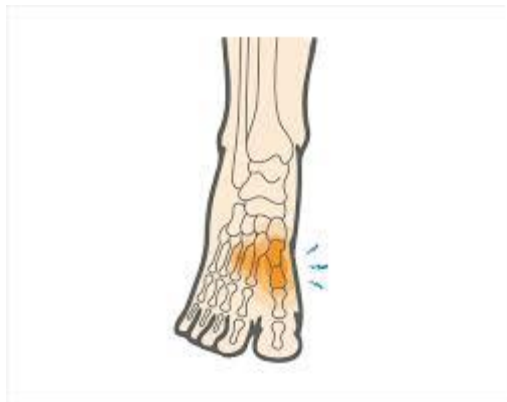

Fig. No. 1.11 : Stress fracture of metatarsal bone

Swelling, heat, redness, and discomfort are common symptoms of tendonitis. Tendonitis is an inflammation of a tendon or the covering of a tendon.

Tendonitis is produced by a succession of little stressors that irritate the tendon repeatedly. Repetitive stretching can induce tendon inflammation.

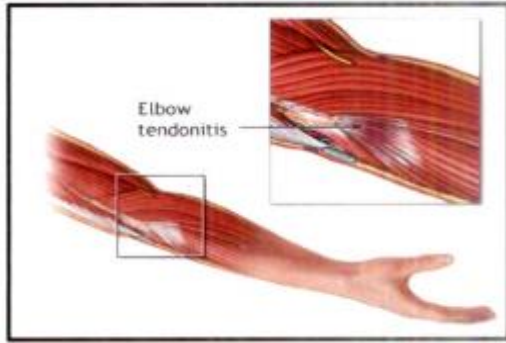


Fig. No. 1.12 : Elbow tendonitis

Bursitis is a condition in which a bursa, a fluid-filled sac situated between a bone and a tendon or muscle, becomes inflamed. A bursa permits the tendon to glide over the bone smoothly. The bursa in the shoulder, elbow, hip, knee, or ankle might enlarge because of repeated minor stressors and misuse. Bursitis is the medical term for this swelling and inflammation.

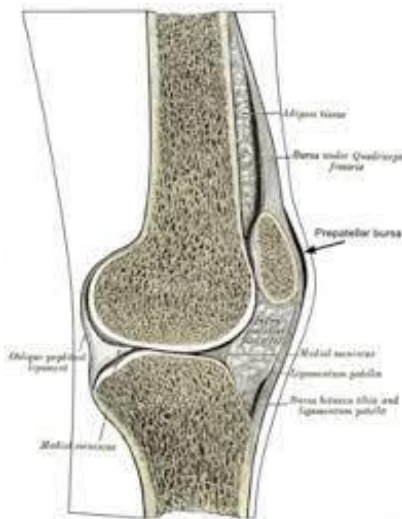


Fig. No. 1.13: Bursa

REFERENCES :

1. **Rensburgy, J. V.**, (2011). Overview of clinical examination and management of sports injuries in adults. *South Africa Family Practice*. 53(1):21 -27.
2. **Ristolainen, L.**, et al., (2009). Gender differences in sport injury and types of injuries: A retrospective twelve month study on cross country skiers, swimmers, long distance runner & soccer players. *Journal of Sports Science & Medicine*, Vol 8, 443-451.

3. **Roy, S., Irvin, R.,** (1983). Sports Medicine: Prevention, Evaluation, Management and Rehabilitation. New Jersey, Engle Wood Cliffs. p.p. 1 - 20, 113 - 114.
4. **Zebas, C., and Chapman, M.** (1990). Prevention of sports injuries: A biomechanical approach, USA, Eddie Bowers, p. 153.
5. **Zemper, E. D.,** (2010). The rate of catastrophic injuries among young athletes. British Journal of Sports Medicine. 44(1): 13-20.
6. **Zemper, E.D.,** (1991). Exercise and injury patterns in a sample of active middle aged adults. International Congress of Sports Medicine and Human Performance, in Vancouver, B.C., Canada.